

# Snapping Scapula Syndrome in the Military



Jeanne C. Patzkowski, MD<sup>a,\*</sup>, Brett D. Owens, MD<sup>b</sup>, Travis C. Burns, MD<sup>a</sup>

## KEYWORDS

• Snapping scapula syndrome • Chest wall • Military • Bursa

## KEY POINTS

- Snapping scapula syndrome is caused by abnormal interaction between the scapula and chest wall and may be caused by an osseous or soft tissue mass, abnormal muscle dynamics, or chronic scapulothoracic bursitis.
- Snapping scapula syndrome may be more prevalent in the military because of physical fitness standards requiring intense upper body exercise, prolonged heavy load bearing through the shoulder girdle, and use of protective gear that applies nonphysiologic forces to the scapulothoracic articulation.
- Initial treatment is nonoperative. Corticosteroid injections into inflamed bursae may be diagnostic and therapeutic.
- Arthroscopic bursectomy with partial scapulectomy may help patients who are refractory to nonoperative measures.
- Anatomy of the scapulothoracic articulation is complex and arthroscopy should only be attempted after obtaining a thorough understanding of this region.

## INTRODUCTION: NATURE OF THE PROBLEM

The scapulothoracic joint is a complex, noncongruent articulation between the scapula and the chest wall. Motion and stability of the scapula are controlled through the dynamic interaction of the surrounding musculature. The scapula is a triangular bone with 3 borders (medial, lateral, and superior) and 3 angles (superomedial, inferomedial, and lateral), and the costal surface is concave to match the convexity of the chest wall.<sup>1–3</sup> The acuity of the superomedial angle varies widely, ranging between 124° and 162° relative to the scapular body.<sup>4</sup> Two bursae, the infraserratus and supraserratus, are consistently found in this region. The infraserratus bursa lies between the

---

Disclosure: The views expressed in this article are those of the authors only and do not represent the views of the San Antonio Military Medical Center, Keller Army Community Hospital, the United States Army or Department of Defense.

<sup>a</sup> Orthopaedic Surgery Service, San Antonio Military Medical Center, 3851 Roger Brooke Drive, Fort Sam Houston, TX 78234, USA; <sup>b</sup> Orthopaedic Surgery Service, Keller Army Community Hospital, 900 Washington Road, West Point, NY 10996, USA

\* Corresponding author.

E-mail address: [jeanne.patzkowski@gmail.com](mailto:jeanne.patzkowski@gmail.com)

Clin Sports Med 33 (2014) 757–766

<http://dx.doi.org/10.1016/j.csm.2014.06.003>

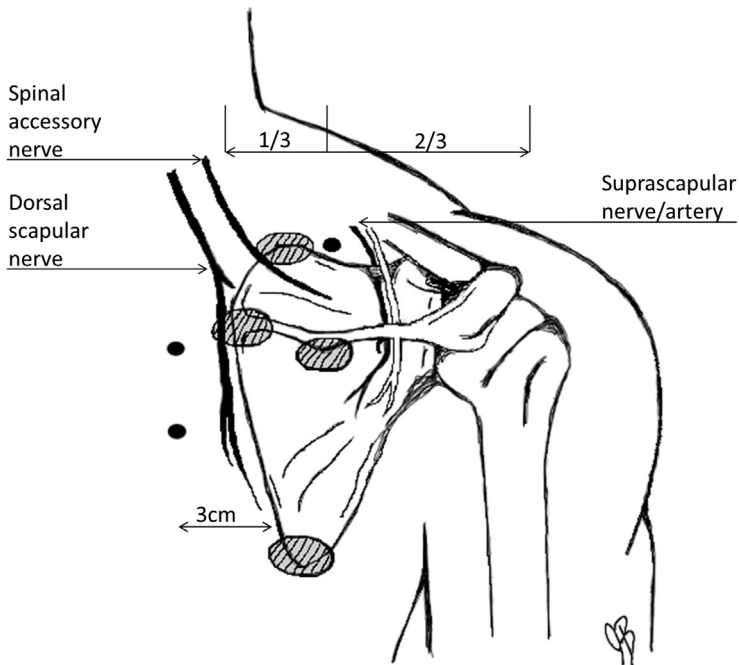
0278-5919/14/\$ – see front matter Published by Elsevier Inc.

[sportsmed.theclinics.com](http://sportsmed.theclinics.com)

serratus anterior muscle and the chest wall, whereas the supraserratus bursa is found between the serratus anterior and subscapularis musculature.<sup>2</sup> Additional minor bursae are variably noted and are considered pathologic. They are typically located at the superomedial angle, inferomedial angle, and at the medial base of the spine of the scapula underneath the trapezius (trapezoid bursa).<sup>2</sup>

Several neurovascular structures lie in the vicinity of the scapula (Fig. 1). The spinal accessory nerve travels on the deep surface of the trapezius and enters the interval between the superomedial scapula and the trapezius lateral to the fibers of the levator scapulae. It crosses the superior border of the scapula approximately 3 cm lateral to the superomedial angle and terminates in the body of the trapezius.<sup>5</sup> A superficial branch of the transverse cervical artery runs alongside the spinal accessory nerve. The dorsal scapular artery and nerve travel approximately 1 cm medial to the medial border of the scapula, deep to the rhomboid major and minor. The long thoracic nerve resides on the anterolateral surface of the serratus anterior and could be injured with far anterior instrumentation in the space between the subscapularis and serratus anterior. The suprascapular artery and nerve run along the superior border of the scapula toward the suprascapular notch.<sup>6,7</sup>

Snapping scapula syndrome may be the result of osseous or soft tissue masses within the scapulothoracic space. Anatomic causes include osseous masses such as osteochondroma, or rarely chondrosarcoma in older patients, elastofibroma, abnormal scapular anatomy (ex. a superomedial scapular angle less than 140 yielding excessive anterior angulation and contact with the rib cage), fibrotic or anomalous muscle, and malunion of scapula or rib fractures.<sup>1-3,8,9</sup> Scapulothoracic bursitis may also be involved in the pathophysiology of snapping scapula syndrome and is likely the result of inflammation related to overuse of the shoulder girdle. With continued



**Fig. 1.** Scapulothoracic anatomy. Black circles represent arthroscopic portals. Dashed ovals represent deep bursae.

irritation, fibrotic changes may take place within the various bursae leading to worsening of symptoms and overt snapping (see [Fig. 1](#)).<sup>10</sup> Postural abnormalities and excessive thoracic kyphosis may alter scapulothoracic motion as well.<sup>11</sup>

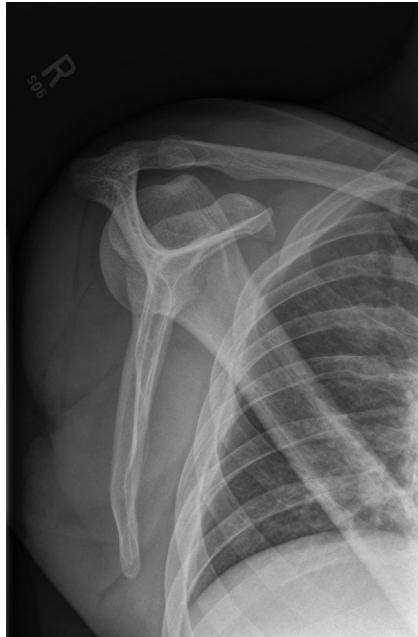Symptoms in snapping scapula syndrome vary widely. Patients may complain of intermittent pain and bursitis or disabling pain and loud crepitus.<sup>1</sup> Pain is typically activity related and may have its onset after a traumatic injury or develop insidiously.<sup>2,3</sup> Symptoms are exacerbated with repetitive overhead activity or push-ups, and are typically located at the superomedial or, less commonly, the inferomedial angle.<sup>2,3</sup> The patient may show winging of the scapula caused by nerve or muscle injury, and there may be a palpable fullness in the setting of an underlying mass.<sup>2</sup>

Military service members must adhere to strict physical fitness standards in order to remain on active duty. Push-ups are among the most common exercises performed in military training and are tested in each of the services' routine physical fitness assessments. Pull-ups, obstacle courses, low crawls, and upper body weight lifting are also frequent components of service members' basic physical fitness routines. During training and deployment scenarios, service members are required to carry 35 to 55 kg (80–120 pounds) of gear for long distances, primarily using upper extremity load-bearing equipment. Although rare, winging of the scapula from nerve injury or rhomboid and trapezius muscle rupture has been reported secondary to backpack use,<sup>12</sup> highlighting the significant burden applied to the shoulder girdle with heavy packs. Historical reports show substantial increases in the loads borne by soldiers during combat operations, and efforts to study load distribution have been underway since the late 1980s. Multiple medical problems have been directly associated with heavy load bearing during military training, including back pain and so-called rucksack palsy. Rucksack palsy is well described and likely related to traction injury of the C5 and C6 nerve roots with symptoms ranging from numbness and cramping to scapular crepitus to permanent scapular winging.<sup>13</sup> In addition to the weight on the shoulder girdle, military packs and body armor plates apply nonphysiologic compressive forces to the scapulothoracic articulation, potentially contributing to malposition, bursitis, and crepitus.

Imaging modalities are an important part of the work-up for snapping scapula syndrome, particularly to rule out bony or soft tissue masses that may be the underlying cause of the pain or crepitus. Plain radiographs consisting of shoulder anteroposterior, lateral scapular, and axillary views are obtained ([Fig. 2](#)). Computed tomography (CT) or magnetic resonance imaging (MRI) of the scapulothoracic articulation may be helpful when physical examination or radiographs raise suspicion for a soft tissue or osseous mass. Three-dimensional CT scanning may be more sensitive than plain radiography and conventional CT for detecting subtle anatomic variations in those patients who fail to respond to conservative management.<sup>14</sup> However, many patients have no identifiable anatomic cause for their symptoms.

Initial management is primarily nonoperative, consisting of activity modification, antiinflammatory medication, and physical therapy. Physical therapy is directed at stretching and strengthening of periscapular musculature, restoring thoracic extension, and postural corrections.<sup>15,16</sup> Corticosteroid injections into inflamed bursae may assist with diagnosis and provide symptomatic relief.<sup>10,15</sup>

For those patients whose symptoms are refractory to nonoperative management, surgery may be beneficial. Surgery is primarily designed to remove the inflamed bursae with partial scapulectomy, which can be performed through open, arthroscopic, or combined techniques. Arthroscopic bursectomy with partial scapulectomy typically requires less dissection of the periscapular musculature and results in quicker rehabilitation.<sup>7,17–22</sup>



**Fig. 2.** Lateral scapula radiograph.

### INDICATIONS/CONTRAINDICATIONS

#### Indications:

- Symptomatic snapping scapula/scapulothoracic bursitis
- Persistent pain and disability after appropriate nonoperative therapy and activity restrictions

#### Contraindications:

- Nerve palsy
- Periscapular muscle wasting
- Thoracic kyphosis
- Voluntary snapping (relative)
- No relief with local anesthetic injection into symptomatic bursa (relative)
- Cervical spine disease (relative)

### SURGICAL TECHNIQUE/PROCEDURE

During preoperative planning it is imperative to ensure that the patient's history and physical examination are consistent with a diagnosis of snapping scapula syndrome or scapulothoracic bursitis. Obtain good quality plain films and CT scan or MRI if there is suspicion for a space-occupying lesion requiring further characterization. If there are any suspected neurologic abnormalities, consider cervical spine imaging or electromyographic studies as indicated.

During surgery, patients may be positioned prone or in the lateral decubitus position. If concomitant glenohumeral arthroscopy is planned, the lateral position is preferred. Anesthesia is typically general with or without the use of a regional nerve

block. The arm is placed into the chicken-wing position of shoulder extension and internal rotation (**Fig. 3**). Table position in 10° to 15° of reverse Trendelenburg may help avoid extravasation of arthroscopy fluid into the neck.

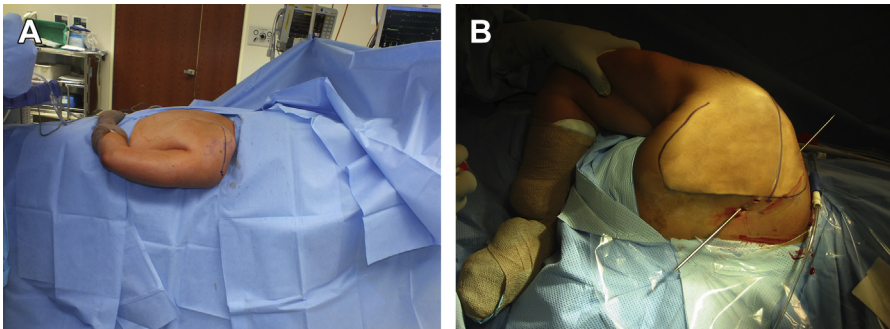
For complete visualization of the scapulothoracic space both the 30° and 70° arthroscope are recommended. A standard 4.5-mm shaver and radiofrequency ablation device should be sufficient for bursectomy. We recommend the 5.5-mm burr for partial scapulectomy.

Before establishing the portals, mark out the superomedial angle of the scapula, lateral acromion, spine of scapula, inferomedial angle, and medial (vertebral) border. Place mark at the junction of the medial and middle thirds on a line between the superomedial angle of the scapula and the lateral border of the acromion (location of the superior portal). Establish the medial portal 2 to 3 cm medial to the medial border of the scapula at or below the level of the scapular spine (**Fig. 4**). Establish a second medial portal inferior to the initial portal if bursectomy is required at the inferomedial angle. The inferior portal can also serve as the viewing portal with the more superior portal used for instrumentation while working on the superomedial angle.

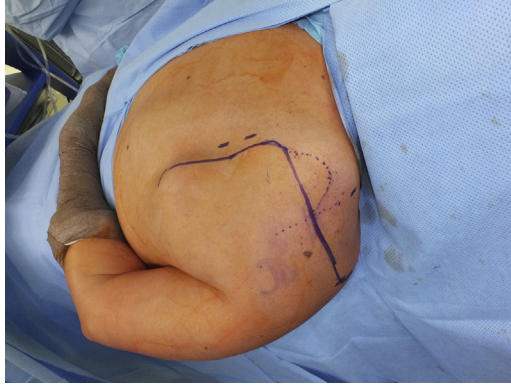
With the arm in the chicken-wing position place the arthroscopic cannula with trocar in the scapulothoracic space with care to direct the blunt cannula parallel to the chest wall. Create the superior portal with an inside-out technique. With the trochar in the superior of the 2 medial portals, direct the trocar superiorly and laterally, aiming for the mark at the junction of the middle one-third and lateral two-thirds of the line between the superomedial angle and lateral acromion.<sup>7</sup> Incise over the palpable tip of the blunt trocar to create the portal (**Fig. 5**).

Remove soft tissue and inflamed bursa from the undersurface of the superomedial corner using radiofrequency wand or shaver, similar to the technique for subacromial bursectomy (**Figs. 6 and 7**). Insert an 18-gauge needle into the medial aspect of scapula 1 cm superior to the scapular spine to mark the medialmost extent of your scapular resection (**Fig. 8**). This technique protects the dorsal scapular nerve and artery, which are located approximately 1 cm medial to the medial border of the scapula.<sup>6</sup> Using the burr, resect bone from the superomedial corner. Medial resection should be limited to the level of the medial needle and lateral resection should be limited to a line connecting the superior portal to a point centered between the inferior pole and the scapular spine (**Figs. 9 and 10**).<sup>18</sup>

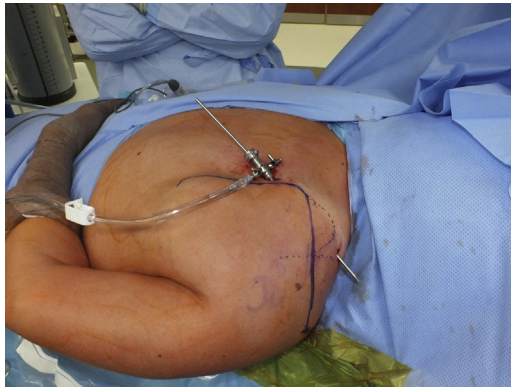The amount of bony resection necessary at the superomedial angle is controversial. Most investigators recommend 2 to 3 cm from the superomedial corner if an obvious



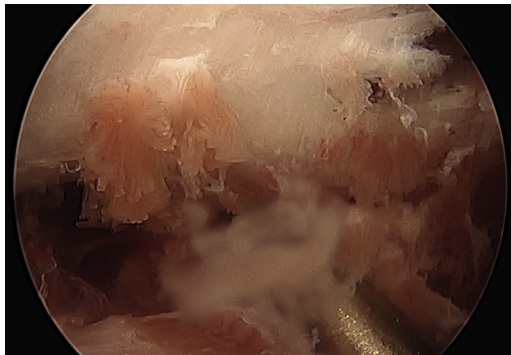
**Fig. 3.** (A) Chicken-wing position for arthroscopy (prone). (B) Chicken-wing position for arthroscopy (lateral decubitus).



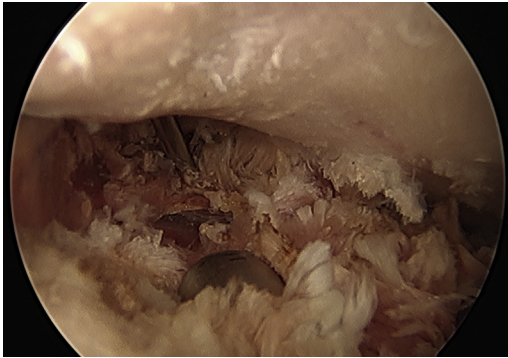
**Fig. 4.** Mark superior and medial portals.



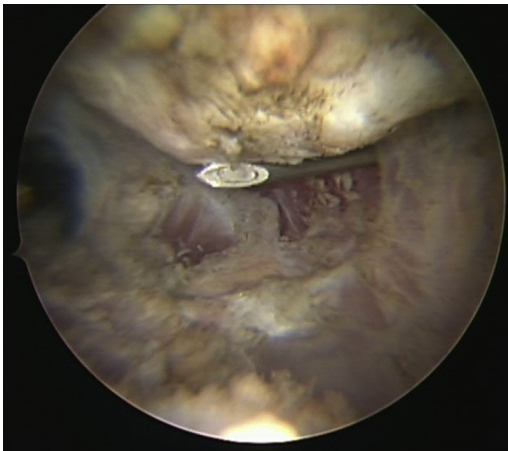
**Fig. 5.** Create superior portal with inside-out technique.



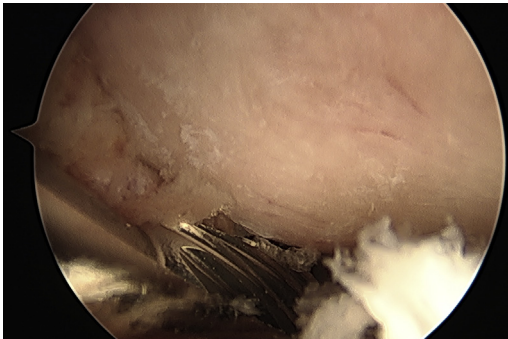
**Fig. 6.** Scapulothoracic bursa.



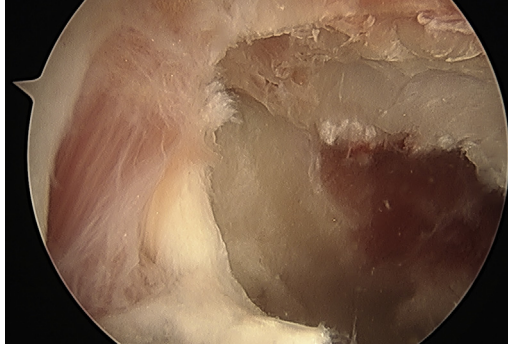
**Fig. 7.** Completed scapulothoracic bursectomy.



**Fig. 8.** Needle localization of superomedial angle of scapula.



**Fig. 9.** Superomedial angle of scapula.



**Fig. 10.** Completed resection.

osseous prominence is not visualized.<sup>18,22</sup> Remember that the findings may be altered secondary to soft tissue distortion from arthroscopy fluid. Portals are closed in a standard fashion with absorbable or nonabsorbable suture and a simple internal rotation sling is applied.

### COMPLICATIONS AND MANAGEMENT

Chest wall penetration is the most serious complication, but is easily prevented with appropriate technique. Keeping the arm in the chicken-wing position elevates the scapula away from the chest wall and facilitates instrument insertion. When entering the scapulothoracic space, always direct the instruments parallel to the chest wall to avoid chest wall penetration.

Multiple neurovascular structures are adjacent to the scapula and at risk during scapulothoracic arthroscopy. In particular, the dorsal scapular nerve and artery and spinal accessory nerve traverse adjacent to the medial border of the scapula. They can be protected by placing the medial portals 2 to 3 cm medial to the medial border of the scapula and below the level of the scapular spine.<sup>6</sup> Avoid use of the shaver or radiofrequency wand medial to the medial border to avoid drawing the structures into the field. The suprascapular nerve travels under the transverse scapular ligament in the suprascapular notch, with the artery traveling above the ligament. These structures are protected by placing the superior portal at the junction of the middle and medial thirds of a line connecting the superomedial border of the scapula to the lateral acromion and limiting lateral bony resection to the previously described safe zone.

Inadequate resection may lead to continued symptoms and failure of the procedure. The proper amount of bony resection is controversial. Performing an examination under anesthesia after resection to ensure no residual crepitus or impingement may help avoid this complication. Excessive resection may be prevented by placing needles at bony landmarks because arthroscopic localization may be challenging. Intraoperative fluoroscopy may help verify landmarks and extent of resection, although its use has not been well described.

### POSTOPERATIVE CARE

Patients are initially immobilized in a sling for comfort. They may discontinue use of the sling within the first week after surgery. Pendulum exercises and passive motion are initiated immediately with progression to active motion and strengthening exercises to tolerance. As patients regain motion, they are referred to supervised physical

therapy to assist with thoracic extension/posture training and periscapular muscle strengthening.

## OUTCOMES

Most reported outcomes are from small retrospective case series. Pearse and colleagues<sup>20</sup> evaluated 13 patients, 10 of whom underwent bursectomy alone, and an additional 3 who had resection of the superomedial angle. Nine reported improvement in their symptoms, 6 were pain free, and 3 reported moderate pain. Eight of 9 patients returned to work and 6 returned to presymptomatic sporting activities. Millett and colleagues<sup>19</sup> evaluated 21 shoulders undergoing scapulothoracic bursectomy alone (2) or bursectomy with partial scapulectomy (19). The overall group had a significant improvement in American Shoulder and Elbow Surgeon (ASES) scores (average score of 53 before surgery improving to 73 after surgery), visual analog scale (VAS) (9 before surgery to 5 after surgery), QuickDASH (shortened version of Disabilities of Arm, and Hand) and Single Assessment Numeric Evaluation (SANE) scores. Younger patients and those who had bursectomy alone were noted to have smaller improvements in ASES scores and to be less satisfied overall with their care. Three (13%) required revision for persistent pain and crepitus. Pavlik and colleagues<sup>17</sup> reported on 10 patients undergoing arthroscopic bursectomy with partial scapulectomy and noted complete resolution of symptoms in 2 patients, decreased symptoms in 8, and subjective good/excellent results in 9. Only 1 patient reported that residual symptoms were bothersome. Nine of 10 returned to work and 6 of 9 returned to previous sporting activity. Each report emphasizes the importance of proper patient selection, and shows that good results do not necessarily imply complete resolution of symptoms.

## SUMMARY

Snapping scapula syndrome is a rare condition resulting in painful crepitus of the scapulothoracic articulation that may be more common in a military population because of significant upper extremity load-bearing activities. Conservative management is the first-line therapy and is successful in up to 80% of patients. For those patients who fail conservative management, arthroscopic bursectomy and partial scapulectomy is a reasonable option, but is technically demanding and requires an in-depth understanding of the complex anatomy of the scapulothoracic region.

## REFERENCES

1. Gaskill T, Millett PJ. Snapping scapula syndrome: diagnosis and management. *J Am Acad Orthop Surg* 2013;21:214–24.
2. Kuhne M, Boniquit N, Ghodadra N, et al. The snapping scapula: diagnosis and treatment. *Arthroscopy* 2009;25:1298–311.
3. Lazar MA, Kwon YW, Rokito AS. Snapping scapula syndrome. *J Bone Joint Surg Am* 2009;91:2251–62.
4. Aggarwal A, Wahee P, Harjeet, et al. Variable osseous anatomy of costal surface of scapula and its implications in relation to snapping scapula syndrome. *Surg Radiol Anat* 2011;33:135–40.
5. Williams GR, Shakil M, Klimkiewicz J, et al. Anatomy of the scapulothoracic articulation. *Clin Orthop Relat Res* 1999;359:237–46.
6. Ruland LJ, Ruland CM, Mathews LS. Scapulothoracic anatomy for the arthroscopist. *Arthroscopy* 1995;11:52–6.

7. Chan B, Chakrabarti AJ, Bell SN. An alternative portal for scapulothoracic arthroscopy. *J Shoulder Elbow Surg* 2002;11:235–8.
8. Edelson JG. Variations in the anatomy of the scapula with reference to the snapping scapula. *Clin Orthop Relat Res* 1996;322:111–5.
9. Totlis T, Konstantinidis GA, Karanassos MT, et al. Bony structures related to snapping scapula: correlation to gender, side and age. *Surg Radiol Anat* 2013;36(1):3–9.
10. Kuhn JE, Plancher KD, Hawkins RJ. Symptomatic scapulothoracic crepitus and bursitis. *J Am Acad Orthop Surg* 1998;6:267–73.
11. Kibler WB, McMullen J. Scapular dyskinesis and its relation to shoulder pain. *J Am Acad Orthop Surg* 2003;11:142–51.
12. Lee S, Kim J, Lee S, et al. Winged scapula caused by rhomboideus and trapezius muscles rupture associated with repetitive minor trauma: a case report. *J Korean Med Sci* 2006;214:581–4.
13. Knapick JJ, Reynolds KL, Harman E. Soldier load carriage: historical, physiological, biomechanical and medical aspects. *Mil Med* 2004;169:45–56.
14. Mozes G, Bickels J, Ovadia D, et al. The use of three-dimensional computed tomography in evaluating snapping scapula syndrome. *Orthopedics* 1999;22:1029–33.
15. Manske RC, Reiman MP, Stovak ML. Nonoperative and operative management of snapping scapula. *Am J Sports Med* 2004;32:1554–65.
16. Conduah AH, Baker CL, Baker CL. Clinical management of scapulothoracic bursitis and the snapping scapula. *Sports Health* 2010;2:147–55.
17. Pavlik A, Ang K, Coghlan J, et al. Arthroscopic treatment of painful snapping of the scapula by using a new superior portal. *Arthroscopy* 2003;19:608–12.
18. Bell SN, van Riet RP. Safe zone for arthroscopic resection of the superomedial scapular border in the treatment of snapping scapula syndrome. *J Shoulder Elbow Surg* 2008;17:647–9.
19. Millett PJ, Gaskill TR, Horan MP, et al. Technique and outcomes of arthroscopic scapulothoracic bursectomy and partial scapulectomy. *Arthroscopy* 2012;28:1776–83.
20. Pearse EO, Bruguera J, Massoud SM, et al. Arthroscopic management of the painful snapping scapula. *Arthroscopy* 2006;22:755–61.
21. Blond L, Rechter S. Arthroscopic treatment for snapping scapula: a prospective case series. *Eur J Orthop Surg Traumatol* 2013;24(2):159–64.
22. Lehtinen JT, Tetreault P, Warner JJ. Arthroscopic management of painful and stiff scapulothoracic articulation. *Arthroscopy* 2003;19(4):E28.